



## PATIENT PRESENTING CLINICAL SIGNS

**Gypsy Chaca** • Anorexia, not drinking, lethargy for 24 hours and possible nausea. Unsure of urinating for past 24 hours. Possible abdominal effort when breathing.

**SPECIES** Abnormal PE/Chem/CBC/UA Results: 5-8% dehydration. SQ mass on LEFT side of neck. Temp=102.5...cbc/chem/ua pending

Feline

## RADIOGRAPHIC STUDY OF THE THORAX AND ABDOMEN

**BREED** Right/left lateral and ventrodorsal views of thorax and abdomen totaling 4 images available for review in JPEG format.

DSH

## RADIOGRAPHIC FINDINGS

### SEX THORAX

FS

The cardiac silhouette presents within normal radiographic limits. No overall enlargement or chamber enlargement is seen. The vertebral heart score is 7.1.

### AGE

5yr

A mild bronchial lung pattern is noted. The lungs are otherwise normal. No evidence of consolidation, infiltrates, nodules or masses.

The cranioventral opacity noted on lateral views corresponds to the mediastinal reflection which is a normal anatomical finding. The mediastinum appears normal.

## INTERPRETED BY

Nele Eley (Ondreka),  
DVM Dr. med. vet.,  
DipECVDI

The pleural spaces present normal.

### ABDOMEN

The abdominal wall is smooth and thin.

## HOSPITAL NAME

Northvale Veterinary  
Clinic

The serosal detail is maintained throughout the peritoneal and retroperitoneal space.

The liver is appropriate in position, size and presents uniform opacity.

The splenic head is in the anticipated position and within normal limits for size and opacity. The splenic tail is not seen.

## REFERRING VET

Dr Stefanie Simon

Both kidneys are seen and present with normal size, shape, delineation and opacity. The urinary bladder is in its anticipated position. No radiopaque calculi are noted throughout the upper and lower urinary tract.

## INVOICE

23739

The stomach is in its anticipated position and presents normal content.

The small intestinal loops are of even diameter and non-dilated, a small amount of gas is seen within the small intestinal loops and considered within normal limits.

## DATE

02/01/2026

Fecal matter appears to be slightly impacted within the descending colon.



## PATIENT RADIOGRAPHIC DIAGNOSIS

Gypsy Chaca

- Mild bronchial lung pattern, within age-related normal limits
- Cranioventral opacity is normal mediastinal reflection
- No pulmonary consolidation or mass noted
- Normal radiographic presentation of the abdomen
- Constipation of the colon noted

## SPECIES

Feline

## INTERPRETATION OF FINDINGS & FURTHER RECOMMENDATIONS

### BREED

DSH

The cranioventral opacity in the thoracic lateral views can mimic pulmonary consolidation or infiltrates but corresponds to the normal cranioventral mediastinal reflection and is not indicative of pathology.

### SEX

FS

The mild bronchial markings may reflect nonspecific airway changes. Clinical correlation is recommended.

### AGE

5yr

Constipation may contribute to the abdominal discomfort. Significant abdominal radiographic abnormalities were not identified however further definition by means of abdominal ultrasound could be considered in order to rule out parenchymal disease or gastrointestinal changes occult on radiograph.

## INTERPRETED BY

Nele Eley (Ondreka),  
DVM Dr. med. vet.,  
DipECVDI

## HOSPITAL NAME

Northvale Veterinary  
Clinic

## REFERRING VET

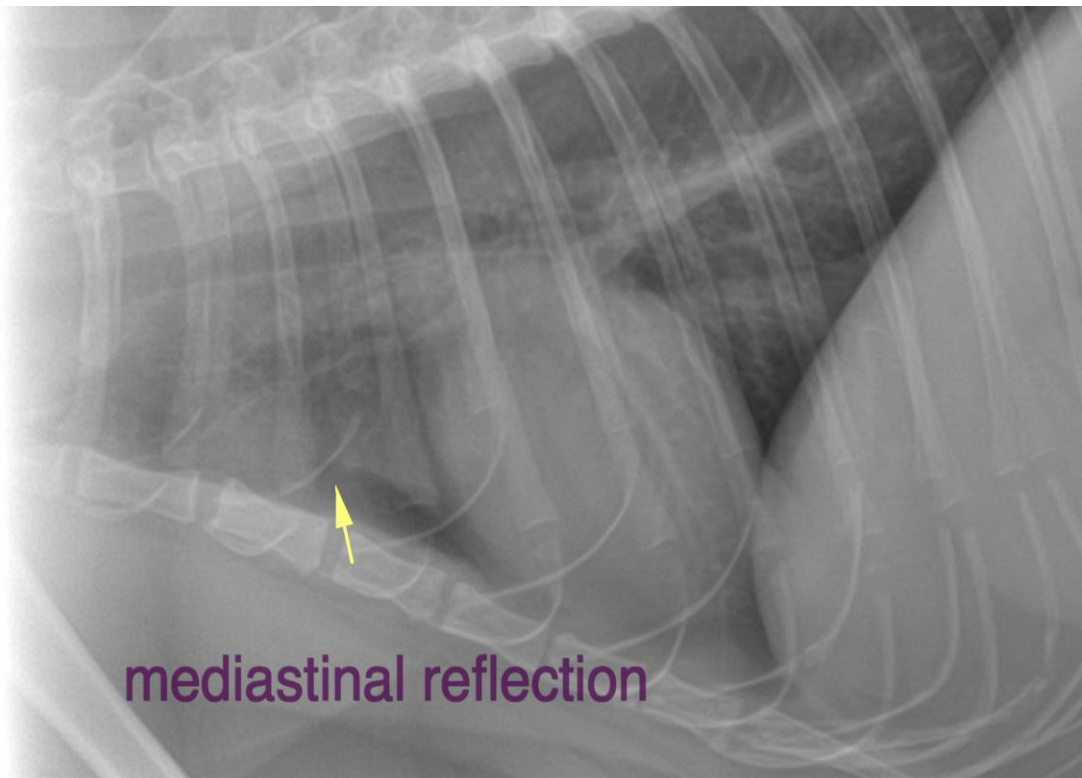
Dr Stefanie Simon

## INVOICE

23739

## DATE

02/01/2026





## PATIENT

Gypsy Chaca

The information and recommendations provided are based on the images presented by the referring veterinarian. No evaluation can be communicated regarding pathology that was not visible in the image/video clips provided.

## SPECIES

Feline

Thank you for this referral. If the clinical or image interpretation does not parallel your findings or if I can be of any further assistance please contact me.

## BREED

DSH

**Nele Eley (Ondreka)**, DVM, Dr. med. vet., DipECVDI  
European Specialist in Veterinary Diagnostic Imaging, Cert. Radiology,  
Senior lecturer University of Giessen/Germany, Veterinary Faculty, Department of Radiology.  
[info@sonopath.com](mailto:info@sonopath.com)

## SEX

FS

## AGE

5yr

## INTERPRETED BY

Nele Eley (Ondreka),  
DVM Dr. med. vet.,  
DipECVDI

## HOSPITAL NAME

Northvale Veterinary  
Clinic

## REFERRING VET

Dr Stefanie Simon

## INVOICE

23739

## DATE

02/01/2026